CASE RECORDS of the MASSACHUSETTS GENERAL HOSPITAL

Founded by Richard C. Cabot
Eric S. Rosenberg, M.D., *Editor*
David M. Dudzinski, M.D., Meridale V. Baggett, M.D., Daniel Restrepo, M.D.,
Dennis C. Sgroi, M.D., Jo-Anne O. Shepard, M.D., *Associate Editors*, Emily K. McDonald, *Production Editor*

# Case 8-2026: A 57-Year-Old Woman with Chest Pain, Dyspnea, and Syncope

Patrick T. O'Gara, M.D.,[1,2] Rachel L. Goldberg, M.D.,[2,3]
Jennifer S.N. Tang, M.B., B.S.,[4,5] Evan D. Gale, M.D.,[2,3]
Eric M. Isselbacher, M.D.,[2,3] Serguei Melnitchouk, M.D., M.P.H.,[6,7]
and Anthony R. Russo, M.D.[8,9]

## PRESENTATION OF CASE

*Dr. Rachel L. Goldberg:* A 57-year-old woman was evaluated at this hospital because of 2 days of chest pain, dyspnea, lightheadedness, and syncopal episodes.

Six weeks before this evaluation, the patient was admitted to this hospital because of a temperature of 41.1°C, dyspnea and hypoxemia, tachycardia, altered mental status, and opioid injection. The results of blood and urine cultures and imaging of the chest, abdomen, pelvis, head, and neck were unrevealing. Transthoracic echocardiography (TTE) revealed thickening of the mitral-valve leaflets and the noncoronary aortic-valve leaflet and no pericardial effusion. The patient received treatment for hypoxemic respiratory failure with mechanical ventilation, a brief course of empirical broad-spectrum antibiotic therapy, diuretic therapy, and albuterol and ipratropium bromide nebulizers. In addition, methadone therapy was started to alleviate the symptoms of opioid withdrawal. Her mental status and respiratory status improved, and she was discharged on hospital day 10 in stable condition.

The patient was in her usual state of health until 2 days before the current admission, when central, nonexertional, and nonradiating chest tightness developed while she was sleeping. On the evening of admission, the chest tightness increased in intensity; at its maximal intensity, she rated it at 10 on a scale of 0 to 10, with 10 indicating the most severe pain. The patient noted dyspnea at rest, lightheadedness, and an increased respiratory rate, and she subsequently insufflated illicit fentanyl.

Twenty minutes after the insufflation of fentanyl, the patient noted worsening dyspnea, and she called emergency medical services. During the emergency medical services assessment, two brief syncopal episodes occurred without a prodrome or apparent seizure activity. The heart rate and the blood pressure were reported as difficult to measure, with the heart rate ranging from 38 to 68 beats per minute and a systolic blood pressure as low as 70 mm Hg; the respiratory rate was 43 breaths per minute, and the oxygen saturation was 93% while the patient was breathing ambient air. A fingerstick blood glucose level was normal. Oral aspirin was administered, and the patient was brought to the emergency department of this hospital.

Author affiliations are listed at the end of the article.

N Engl J Med 2026;394:1111-21.
DOI: 10.1056/NEJMcpc2517857
*Copyright © 2026 Massachusetts Medical Society.*



The New England Journal of Medicine is produced by NEJM Group, a division of the Massachusetts Medical Society.
Downloaded from nejm.org by TOM HSIUNG on March 15, 2026.
Copyright © 2026 Massachusetts Medical Society. All rights reserved, including those for text and data mining, AI training, and similar technologies.

A review of systems was notable for several weeks of a cough productive of yellow sputum, orthopnea, progressive dyspnea on exertion, and exercise intolerance, as well as chills and lightheadedness. The patient reported no fever, weight change, anorexia, nausea, emesis, change in bowel habits, dysuria, rash, or muscle or joint pain. Her medical history was notable for chronic severe sciatic neuropathy, transient ischemic attack, chronic obstructive pulmonary disease, bipolar disorder, anxiety, post-traumatic stress disorder, substance use disorder, iron deficiency anemia, hepatitis C virus infection, alcohol-associated hepatitis, pancreatitis, cellulitis, degenerative disk disease, and lumbar radiculopathy. Medications included oral aspirin, atorvastatin, ferrous sulfate, gabapentin, and methadone, as well as transdermal nicotine and as-needed inhaled albuterol. She had no known adverse reactions to medications.

*A video showing diagnostic imaging is available at NEJM.org*

The patient lived in an urban area of Massachusetts with her family. Owing to severe back pain and neuropathy, she was unable to continue working and had had periods of homelessness. Her family history was notable for diabetes and substance use disorders in several relatives, liver cancer in her father, and metastatic lung cancer in her mother. She had a history of heavy alcohol use, which had been complicated by alcohol-associated hepatitis and pancreatitis; she had not used alcohol in the 15 years before this evaluation. She was a current smoker and had smoked more than one pack of cigarettes per day for over 40 years. She had opioid use disorder, which had started three decades earlier with the use of intravenous heroin with shared needles. In the previous 3 years, the patient had also insufflated fentanyl owing to insufficient venous access; opioid overdoses requiring naloxone had occurred, with the most recent overdose occurring 2 weeks before this admission. Previous attempts with inpatient treatment and group therapy programs approximately 10 years earlier had yielded the most extended period of sobriety from opioids (4 years). The patient also had a history of amphetamine, crack cocaine, marijuana, nonprescribed gabapentin, and benzodiazepine use.

On examination in the emergency department, the temporal temperature was 35.7°C, the heart rate 108 beats per minute, the blood pressure 79/61 mm Hg, the respiratory rate 30 breaths per minute, and the oxygen saturation 91% while the patient was breathing supplemental oxygen through a nasal cannula at a rate of 6 liters per minute. She was described as critically ill, appearing somnolent, tachypneic, pale, and cool. The lips appeared cyanotic. The pupils were 2 mm in diameter and reactive to light. The jugular venous pressure was 15 cm of water. Cardiac auscultation revealed tachycardia and distant heart sounds with no murmurs, rubs, or gallops. Mild, diffuse tenderness was noted on palpation of the abdomen. The legs were cool to the touch and had mild edema and mottled skin. The remainder of the examination was normal.

An electrocardiogram (ECG) (Fig. 1A) showed sinus tachycardia, premature atrial contraction, baseline artifact, right-axis deviation, a borderline elongated PR interval, and PR-segment depression in the inferior and apical leads with PR-segment elevation in lead aVR. Telemetric monitoring performed at the patient's bedside (Fig. 1B) showed marked variability in the invasive blood pressure and pulse oximetry measurements despite a generally normal cardiac rhythm. Bedside point-of-care ultrasonography showed a large pericardial effusion with diastolic inversion of the right ventricle (Fig. 1C and Video 1A).

The patient received 3 liters of intravenous lactated Ringer's solution, and treatment with norepinephrine and ceftriaxone was started. One hour after presentation to the emergency department, laboratory test results became available. Blood

**Figure 1 (facing page). Initial Cardiac Imaging.**
Imaging studies were obtained on admission. An electrocardiogram (Panel A) shows sinus tachycardia, right-axis deviation, and premature atrial contraction. PR-segment depression is present in the inferior and apical leads with PR-segment elevation in lead aVR. An image from telemetric monitoring that was performed at the patient's bedside (Panel B) shows variability in the arterial (red) and oximetry (blue) waveforms, as compared with the regular sinus tachycardia (green). A point-of-care ultrasound (Panel C) shows a large anterior pericardial effusion causing inversion of the right ventricle and right atrium. A radiograph of the chest (Panel D) shows enlargement of the cardiac silhouette, mild pulmonary edema, and bibasilar atelectasis.



The New England Journal of Medicine is produced by NEJM Group, a division of the Massachusetts Medical Society.
Downloaded from nejm.org by TOM HSIUNG on March 15, 2026.
Copyright © 2026 Massachusetts Medical Society. All rights reserved, including those for text and data mining, AI training, and similar technologies.

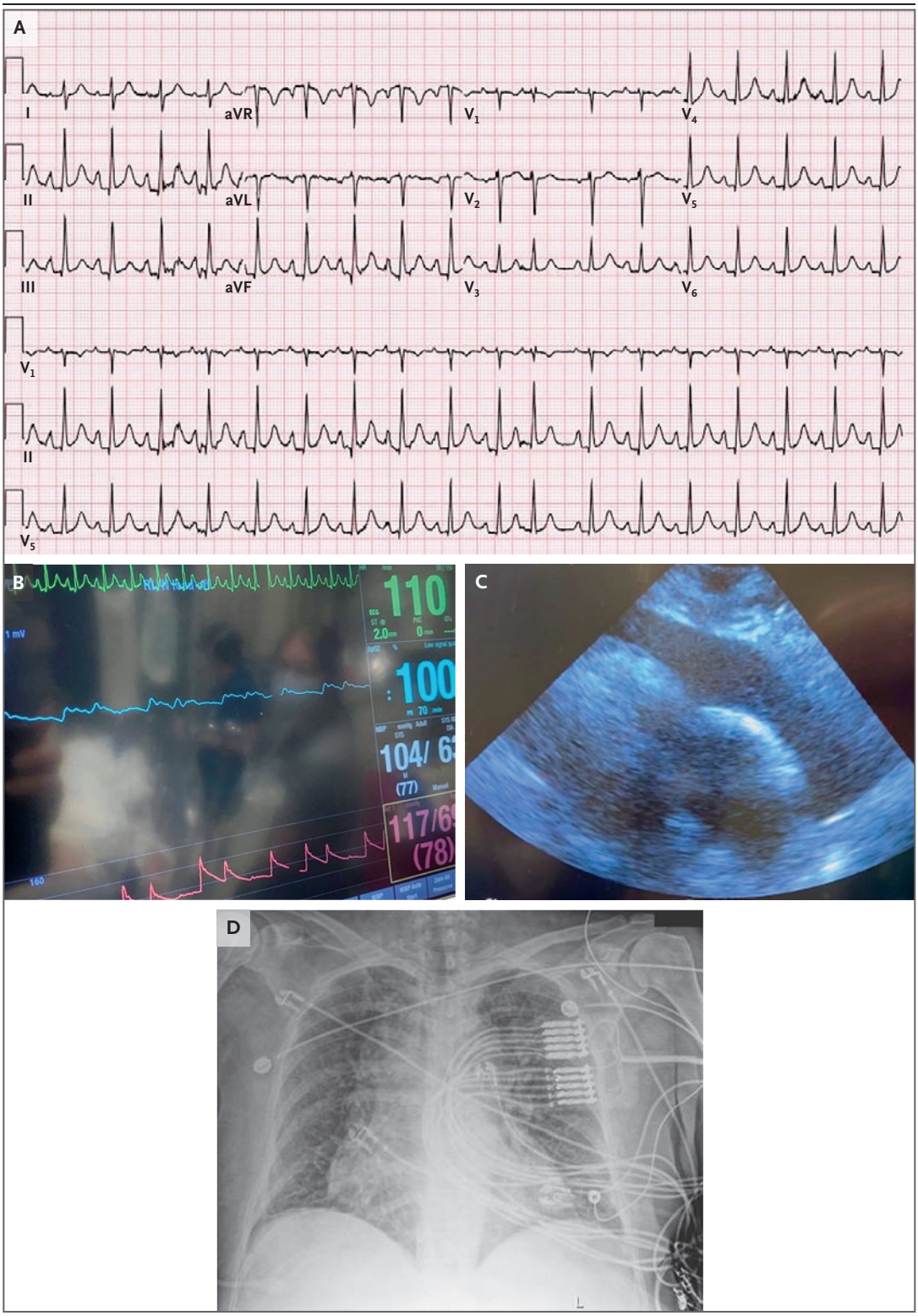




The New England Journal of Medicine is produced by NEJM Group, a division of the Massachusetts Medical Society.
Downloaded from nejm.org by TOM HSIUNG on March 15, 2026.
Copyright © 2026 Massachusetts Medical Society. All rights reserved, including those for text and data mining, AI training, and similar technologies.

levels of magnesium, bilirubin, total protein, and globulin were normal; other laboratory test results are shown in Table 1. Urinalysis was negative. Blood cultures were obtained.

*Dr. Jennifer S.N. Tang:* Chest radiography (Fig. 1D) revealed an enlarged cardiac silhouette, mild pulmonary edema, and bibasilar atelectasis.

*Dr. Goldberg:* The patient underwent urgent pericardiocentesis, which was performed in the cardiac catheterization laboratory with a subxiphoid approach. A pigtail catheter was introduced over a wire. The opening pressure was 35 mm Hg, and 410 ml of bloody, dark fluid was drained. The pigtail catheter was sutured in place. Analysis of the pericardial fluid revealed a total protein level of 6.5 g per deciliter (reference range, 1.7 to 4.6), an albumin level of 3.5 g per deciliter (reference range, 1.2 to 3.1), a lactate dehydrogenase level of 579 U per liter (reference range, 141 to 2613), and a glucose level of 121 mg per deciliter (6.72 mmol per liter; reference range, 80 to 134 mg per deciliter [4.44 to 7.44 mmol per liter]); the erythrocyte count was 2,336,000 per microliter (reference value, <1000), and the total nucleated-cell count was 21,805 per microliter, with 76% neutrophils and 11% lymphocytes.[1] Gram's staining revealed abundant neutrophils and erythrocytes and showed no organisms. The patient was weaned from norepinephrine, treatment with aspirin and colchicine was administered, and her level of alertness increased. The patient was transferred to the cardiac intensive care unit (ICU).

In the cardiac ICU, the heart rate was 91 beats per minute, the blood pressure 155/77 mm Hg (symmetric in both arms), and the oxygen saturation 96% while the patient was breathing supplemental oxygen through a nasal cannula at a rate of 4 liters per minute. The level of thyrotropin was normal, and the hepatitis C virus RNA levels were undetectable; other laboratory test results are shown in Table 1. A urine toxicology screen detected amphetamines, benzodiazepines, buprenorphine, fentanyl, and methadone. Aspiration of pericardial fluid from the pericardial drain with the use of a lure-lock syringe was performed at 4, 12, and 18 hours after the initial procedure and drained 96 ml, 246 ml, and 116 ml of bloody fluid, respectively.

Diagnostic tests were performed, and management decisions were made.

## DIFFERENTIAL DIAGNOSIS

*Dr. Patrick T. O'Gara:* This 57-year-old woman with a long history of polysubstance use disorder was readmitted to this hospital 6 weeks after a previous presentation that was characterized by high fever and hypoxemic respiratory failure, for which no specific cause was found. During that hospitalization, the patient's condition improved after she received supportive care and a brief course of empirical antibiotic therapy.

The current admission occurred after several weeks of progressive shortness of breath, including orthopnea. Progressively worsening recumbent chest tightness developed during the 48 hours leading up to her presentation at the hospital. On examination, the patient was hypotensive with a clinically significant pulsus paradoxus, elevated jugular venous pressure, and distant heart sounds. The presence of a newly accumulated large pericardial effusion with signs of increased intrapericardial pressure was confirmed on point-of-care ultrasonography, and lifesaving percutaneous pericardiocentesis was performed, during which 410 ml of bloody fluid was removed. Drainage of pericardial fluid continued at a substantial rate over the course of the next 18 hours. Gram's staining of the fluid showed abundant neutrophils but no organisms. An immediate cause for this patient's hemorrhagic pericardial effusion was not apparent, which pointed to the urgent need to gather additional information and proceed expeditiously with definitive treatment.

### HEMORRHAGIC PERICARDIAL EFFUSION

The differential diagnosis of a hemorrhagic pericardial effusion was reviewed in the *Journal* in 2023.[2] Many possible causes can be ruled out given the absence of features in the patient history and clinical presentation, such as a recent intracardiac procedure, chest trauma, an acute myocardial infarction, systemic inflammatory disease, or the use of offending medications. Needle-tip migration from a peripheral vein into the central circulation, with erosion through the wall of the venae cavae or chambers on the right side of the heart, has been reported in persons who inject drugs intravenously[3,4]; however, a chest radiograph showed no radiopaque structure within the mediastinum. An occult cancer was not identified during this patient's extensive evaluation 6 weeks earlier.



The New England Journal of Medicine is produced by NEJM Group, a division of the Massachusetts Medical Society.
Downloaded from nejm.org by TOM HSIUNG on March 15, 2026.
Copyright © 2026 Massachusetts Medical Society. All rights reserved, including those for text and data mining, AI training, and similar technologies.

**Table 1. Laboratory Data.***

| Variable | Reference Range, Adults† | On Initial Presentation | Hospital Day 2 |
|---|---|---|---|
| Hemoglobin (g/dl) | 12.0–16.0 | 9.7 | 9.8 |
| Hematocrit (%) | 36.0–46.0 | 29.0 | 28.8 |
| White-cell count (per μl) | 4500–11,000 | 5540 | 8220 |
| Differential count (per μl) | | | |
| Neutrophils | 1800–7700 | 4680 | 7100 |
| Lymphocytes | 1000–4800 | 420 | 490 |
| Monocytes | 200–1200 | 330 | 520 |
| Eosinophils | 0–900 | 50 | 40 |
| Platelet count (per μl) | 150,000–400,000 | 152,000 | 148,000 |
| Sodium (mmol/liter) | 135–145 | 132 | 137 |
| Potassium (mmol/liter) | 3.4–5.0 | 3.4 | 4.3 |
| Chloride (mmol/liter) | 98–108 | 97 | 104 |
| Carbon dioxide (mmol/liter) | 23–32 | 16 | 20 |
| Urea nitrogen (mg/dl) | 8–25 | 16 | 19 |
| Creatinine (mg/dl) | 0.60–1.50 | 1.21 | 1.40 |
| Glucose (mg/dl) | 70–110 | 235 | 168 |
| Phosphorus (mg/dl) | 2.6–4.5 | 4.9 | 4.8 |
| Calcium (mg/dl) | 8.5–10.5 | 8.2 | 8.1 |
| Lactate (mmol/liter) | 0.5–2.0 | 6.6 | 0.9 |
| Albumin (g/dl) | 3.3–5.0 | 3.2 | 3.3 |
| Alanine aminotransferase (U/liter) | 7–33 | 36 | 37 |
| Aspartate aminotransferase (U/liter) | 9–32 | 76 | 73 |
| Alkaline phosphatase (U/liter) | 45–115 | 183 | 173 |
| High-sensitivity troponin T (ng/liter) | 0–9 | 21 | 92 |
| N-terminal pro–B-type natriuretic peptide (pg/ml) | <900 | 1694 | — |
| D-dimer (ng/ml) | <500 | 2283 | — |
| Prothrombin time (sec) | 11.5–14.5 | 16.1 | 16.4 |
| International normalized ratio | 0.9–1.1 | 1.3 | 1.4 |
| Erythrocyte sedimentation rate (mm/hr) | 0–29 | — | 34 |
| C-reactive protein (mg/liter) | <8.0 | — | 88.0 |
| Arterial blood gas | | | |
| Fraction of inspired oxygen | — | Nonrebreather mask | 4 liters/min (nasal cannula) |
| pH | 7.35–7.45 | 7.49 | 7.39 |
| Partial pressure of carbon dioxide (mm Hg) | 35–42 | 15 | 37 |
| Partial pressure of oxygen (mm Hg) | 80–100 | 151 | 85 |

* To convert the values for urea nitrogen to millimoles per liter, multiply by 0.357. To convert the values for creatinine to micromoles per liter, multiply by 88.4. To convert the values for glucose to millimoles per liter, multiply by 0.05551. To convert the values for phosphorus to millimoles per liter, multiply by 0.3229. To convert the values for calcium to millimoles per liter, multiply by 0.250. To convert the values for lactate to milligrams per deciliter, divide by 0.1110.

† Reference values are affected by many variables, including the patient population and the laboratory methods used. The ranges used at the Massachusetts General Hospital are for adults who are not pregnant and do not have medical conditions that could affect the results. They may therefore not be appropriate for all patients.



The New England Journal of Medicine is produced by NEJM Group, a division of the Massachusetts Medical Society.
Downloaded from nejm.org by TOM HSIUNG on March 15, 2026.
Copyright © 2026 Massachusetts Medical Society. All rights reserved, including those for text and data mining, AI training, and similar technologies.

Infection from either a contiguous pulmonary source or hematogenous spread remains a diagnostic possibility, as does an acute type A aortic syndrome.

### CARDIAC TAMPONADE

The patient's physical examination findings of hypotension, elevated jugular venous pressure, and distant heart sounds constitute Beck's triad[5] and are highly consistent with a diagnosis of cardiac compression from a pericardial effusion. In patients with cardiac tamponade, the intrapericardial pressure equals or exceeds the right atrial pressure, rapid early diastolic filling of the right ventricle is impaired, the y descent is blunted or absent, stroke volume is reduced, and the blood pressure decreases. During inspiration, the right ventricle fills at the expense of the left ventricle because of ventricular interdependence, which results in a further decrease in systemic pressure and pulsus paradoxus (a decrease in systolic pressure of 10 mm Hg or greater during inspiration).[6] During expiration, left ventricular filling is restored, but venous return to the right ventricle is impaired by the same mechanism in reverse. Both pericardial compliance and the rate at which intrapericardial fluid accumulates determine the time course over which tamponade develops. Whereas a brisk bleed of 150 to 250 ml into the pericardial space may result in tamponade, malignant pericardial effusions tend to accumulate slowly and may reach volumes of several hundred milliliters before causing hemodynamic compromise.[7] Large-volume effusions are associated with the typical "water bottle" appearance of an enlarged cardiomediastinal silhouette on chest radiography.

Most patients with tamponade report dyspnea; chest pain is a less common symptom. Tachycardia (a compensatory reflex to maintain cardiac output) and elevated jugular venous pressure are reported more often than hypotension in patients with this condition. A structured review of eight studies showed that a pulsus paradoxus greater than 12 mm Hg had 98% sensitivity, 83% specificity, and a positive likelihood ratio of 5.9 (95% confidence interval, 2.4 to 14) for the diagnosis of tamponade.[8] Point-of-care ultrasonography and standard TTE are more sensitive than physical examination and chest radiography for the detection of a pericardial effusion. Tamponade is chiefly a clinical diagnosis supported by echocardiographic findings, including effusion with diastolic right chamber inversion, dilatation of the inferior vena cava, and excessive respirophasic variation in tricuspid and mitral-valve inflows, all of which are indicative of ventricular interdependence. Right ventricular inversion is a more specific but less sensitive marker for tamponade than right atrial inversion.

Computed tomography (CT) of the chest is a sensitive and specific method of detecting a pericardial effusion.[9] CT angiography of the chest is often performed before TTE as part of the rapid process adopted by many emergency departments for the evaluation of dyspnea in a patient whose condition is unstable. A CT angiogram of the chest can provide additional information on pericardial thickness and calcifications, as well as on mediastinal, pulmonary, and great vessel anatomy. On rare occasion, the ECG may show electrical alternans (beat-to-beat changes in voltage), sometimes with reversed polarity, a finding that reflects the swinging motion of the heart within a large effusion. ECG findings of acute pericarditis, such as the PR-segment deviations described in this patient's case, may also be seen. In most instances, the physical examination and TTE suffice to establish the diagnosis of cardiac tamponade and initiate a treatment plan.

### INFECTION OF THE PERICARDIAL SPACE

Infection of the pericardial space would be considered in this patient, given her chronic medical conditions, including polysubstance use disorder, and housing instability. She had a chronic cough productive of yellow sputum without any reported changes in character that had been treated empirically with antibiotics during her previous admission, which may have masked an indolent infection. There are several infectious causes of a bloody pericardial effusion, including tuberculosis, pyogenic bacteria (e.g., staphylococcus and streptococcus species), and fungi.

Tuberculous pericarditis can be difficult to diagnose and treat; however, its incidence in developed countries has declined steadily over time.[10-12] The effusions usually have lymphocytic predominance; acid-fast bacilli may not be seen even with special staining, and additional studies, such as pericardial biopsy and testing for adenosine deaminase activity in the pericardial fluid, are typically needed to establish the diagnosis.[13,14] The absence of organisms on Gram's staining of the fluid would suggest against the possibility of a bacterial pericardial infection. Bacteremia was not a feature of this patient's previous presenta-



The New England Journal of Medicine is produced by NEJM Group, a division of the Massachusetts Medical Society.
Downloaded from nejm.org by TOM HSIUNG on March 15, 2026.
Copyright © 2026 Massachusetts Medical Society. All rights reserved, including those for text and data mining, AI training, and similar technologies.

tion, and no signs of pneumonia were seen on chest imaging at admission. Nevertheless, infection cannot be entirely ruled out in this vulnerable patient. The continued and voluminous bloody pericardial drainage requires more immediate attention than antibiotic therapy alone.

#### ACUTE AORTIC SYNDROMES

Acute aortic syndromes comprise dissection, intramural hematoma, penetrating ulcer, transection, and abrupt aneurysm expansion with threatened or contained rupture.[15] Involvement of the aortic root and proximal ascending aorta, over which the pericardial reflection extends, can result in the rapid accumulation of blood in the pericardial space, tamponade, syncope, and death. Among these syndromes, dissection and contained rupture (pseudoaneurysm formation) are the most likely possibilities in this patient. The absence of traditional risk factors for dissection (e.g., hypertension, a family history of aortic disease, a connective-tissue disease, previous aortic manipulation, bicuspid aortic-valve disease, and known aortic aneurysm) would not rule out its potential occurrence. Rupture would need to be explained by an underlying process that affects the integrity of all three layers of the aortic wall, thus allowing blood under systemic pressure to exit the circulation and fill the pericardial space.

At this point in the evaluation, there are not enough data to determine the cause of this patient's hemorrhagic pericardial effusion with features consistent with tamponade. The next step in the assessment would be to obtain an emergency chest or cardiac CT angiogram to visualize the aortic root and proximal aorta, the aortic valve, the coronary arteries, the pericardium, and the surrounding mediastinal structures. Surgical intervention for her life-threatening illness may be indicated.

## INITIAL MANAGEMENT AND CLINICAL IMPRESSION

*Dr. Eric M. Isselbacher*: On the basis of findings on point-of-care ultrasonography and analysis of the fluid obtained from pericardiocentesis, it was determined that this patient had hemopericardium, and, given that she had presented with acute cardiac tamponade, the hemopericardium was most likely acute. In this clinical setting, the most likely cause of hemopericardium was an acute aortic rupture. Pericardiocentesis is only a temporizing measure in this context, since the risk of death from an acute increase in the flow from the aorta into the pericardium is still high in this patient. Therefore, definitive management of acute hemopericardium due to aortic rupture requires urgent cardiac surgery with repair of the affected segment of the aorta. To establish the diagnosis of acute aortic rupture, CT angiography of the chest was recommended. However, the patient was having severe pain related to opioid withdrawal and repeatedly declined to undergo further testing. It was clear that her opioid withdrawal had to be managed first, before moving forward with other clinical care services.

*Dr. Evan D. Gale:* The patient stated that, before the hospitalization, she had ingested an unspecified number of nonprescribed clonazepam pills daily and insufflated 1.5 g of illicit fentanyl daily. On admission, she confirmed having symptoms of withdrawal from both substances.

Benzodiazepine withdrawal can be challenging to manage because the composition of nonprescribed benzodiazepines is unpredictable[16] and also because there is no validated assessment tool for inpatient management of benzodiazepine withdrawal syndrome. The patient received benzodiazepine withdrawal therapy guided by the Clinical Institute Withdrawal Assessment for Alcohol–Revised (CIWA-Ar). Although this tool is validated for alcohol withdrawal, it was used in this case as a proxy measure, given that alcohol and benzodiazepine withdrawal syndromes both stem from effects on the neurotransmitter $\gamma$-aminobutyric acid.

After outpatient methadone dose verification, home methadone therapy was continued for the management of opioid withdrawal. As-needed clonidine was initially prescribed but then discontinued owing to concerns about the possibility of a negative effect on the patient's cardiac status. The addiction medicine team saw the patient the next morning and did not recommend any adjustment to the withdrawal treatment regimen because she was somnolent. However, she woke up later in the day and reported increased pain related to withdrawal, and she again declined to undergo additional diagnostic testing until the withdrawal symptoms were better addressed. She received doses of short-acting opioids for pain and agreed to undergo CT angiography of the chest once the pain was adequately controlled.

*Dr. Tang:* A CT angiogram of the chest obtained



The New England Journal of Medicine is produced by NEJM Group, a division of the Massachusetts Medical Society.
Downloaded from nejm.org by TOM HSIUNG on March 15, 2026.
Copyright © 2026 Massachusetts Medical Society. All rights reserved, including those for text and data mining, AI training, and similar technologies.

on hospital day 2 (Fig. 2) showed an aortic-root pseudoaneurysm, measuring 8 mm in diameter, arising from the noncoronary sinus of Valsalva. There was a moderate pericardial effusion of intermediate-to-high density with a pericardial drain in place.

## CLINICAL DIAGNOSIS

Hemorrhagic pericardial effusion due to acute aortic rupture.

## DR. PATRICK T. O'GARA'S DIAGNOSIS

Hemopericardium in the context of aortic-root or ascending aortic rupture.

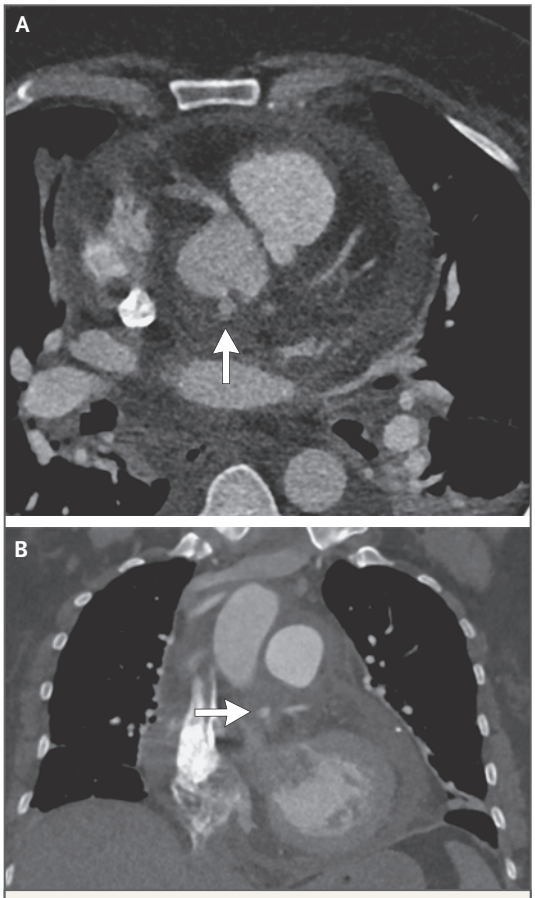


**Figure 2. CT Angiogram of the Chest.**
An axial CT angiogram of the chest performed on hospital day 2 (Panel A) shows a pseudoaneurysm arising from the noncoronary cusp of the sinus of Valsalva (arrow). A coronal CT angiogram performed on hospital day 2 (Panel B) shows a moderate pericardial effusion of intermediate-to-high density, which also surrounds the pseudoaneurysm (arrow).

## OPERATIVE MANAGEMENT

*Dr. Goldberg:* Later the same evening, the patient was taken to the operating room for an urgent aortic-root replacement. Intraoperative transesophageal echocardiography (TEE) was performed (Fig. 3 and Video 1B through 1G). Mild aortic regurgitation and increased thickening of the anterior mitral-valve leaflet were observed, findings that would arouse concern for infection (Fig. 3A and 3B). The TEE also revealed vegetation on the noncoronary leaflet of the aortic valve and an aortic pseudoaneurysm, measuring 21 mm by 16 mm (Fig. 3C through 3F).

*Dr. Serguei Melnitchouk:* On opening the pericardium, diffuse fibrinous material was seen around the entire heart surface. The aorta itself appeared thickened and inflamed. After standard cannulation was performed and cardiopulmonary bypass was initiated, the aorta was cross-clamped, the heart was arrested with antegrade and retrograde cardioplegia, and the aorta was opened transversely above the sinotubular junction. On inspection, there was vegetation on a thickened noncoronary leaflet of the aortic valve and an abscess cavity in the aortic wall of the noncoronary sinus. The aortic-valve leaflets were resected, coronary buttons were prepared, and the aortic-root tissue was resected above the aortic-valve annulus. Both the aortic-valve leaflets and aortic-wall tissues were sent for microbiologic and pathological examination.

The mitral valve was exposed with the use of a transseptal approach. The anterior leaflet of the mitral valve appeared very thickened and inflamed. The resected anterior leaflet was sent for pathological analysis, and a mitral-valve replacement was performed with implantation of a bioprosthetic porcine tissue valve. Aortic-root replacement was performed with the use of a Dacron tube graft and a bovine pericardial tissue valve, followed by reimplantation of the coronary buttons and the distal anastomosis of the Dacron graft to the distal ascending aorta.

Despite robust biventricular function, an attempt to come off the cardiopulmonary bypass was unsuccessful owing to poor oxygenation in the context of severely compromised lung function at baseline. Peripheral venovenous extracorporeal membrane oxygenation (ECMO) was initiated, and the patient was transferred to the ICU.



The New England Journal of Medicine is produced by NEJM Group, a division of the Massachusetts Medical Society.
Downloaded from nejm.org by TOM HSIUNG on March 15, 2026.
Copyright © 2026 Massachusetts Medical Society. All rights reserved, including those for text and data mining, AI training, and similar technologies.

## PATHOLOGICAL DISCUSSION

*Dr. Anthony R. Russo:* A fungal wet preparation of material from the intraoperative swabs of the aortic-root abscess revealed rare fungal elements; subsequently, cultures grew a mold, which was identified as *Aspergillus flavus*. Histologic evaluation of the aortic valve (Fig. 4A) and the mitral valve revealed mixed acute and chronic inflammation, findings that are indicative of acute endocarditis. Grocott's methenamine–silver staining of the aortic valve and the mitral valve (Fig. 4B)

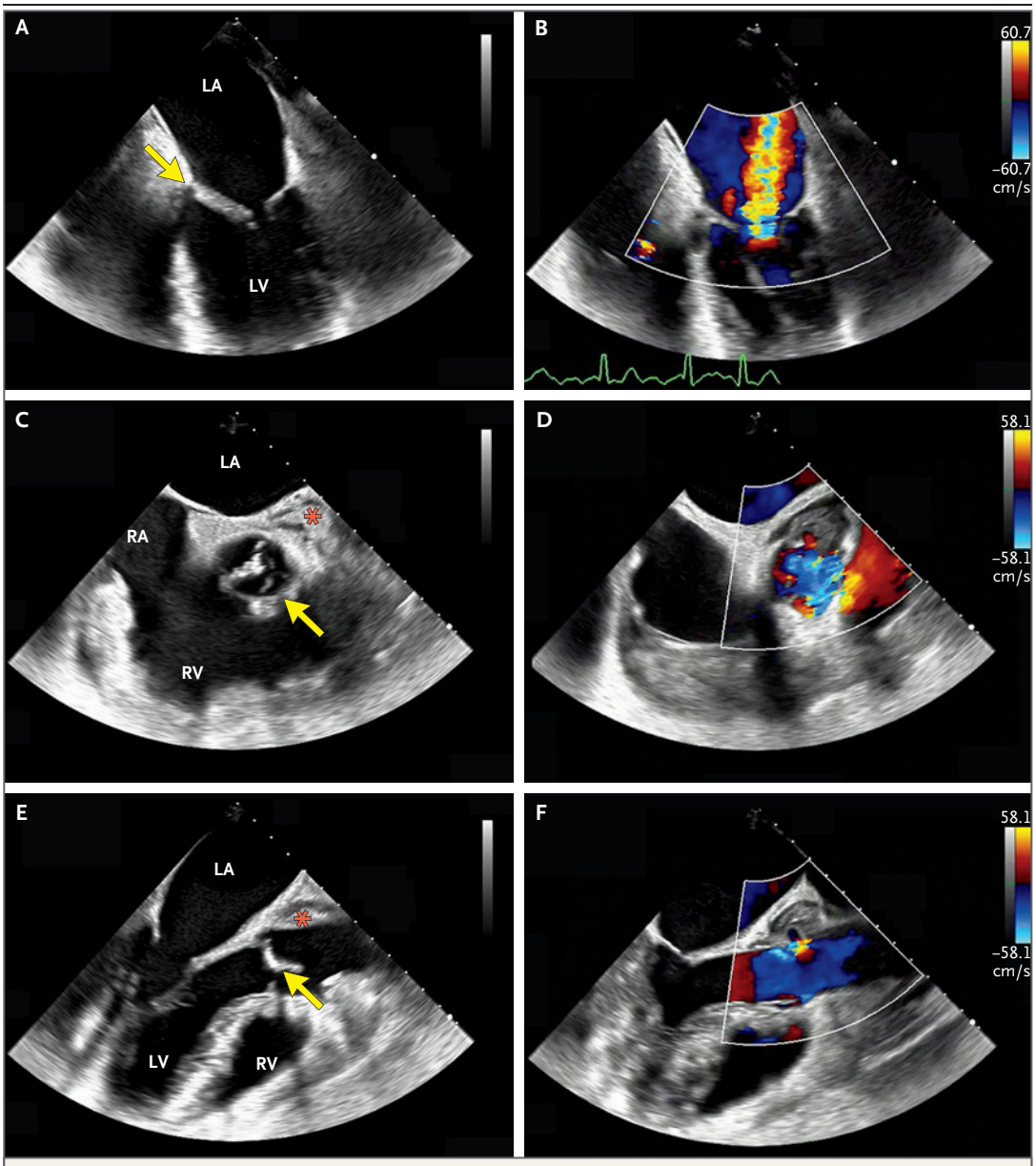


**Figure 3. Intraoperative Transesophageal Echocardiogram.**

Two-dimensional transesophageal echocardiography was performed during surgery for urgent aortic-root replacement. A four-chamber view (Panel A) shows thickening of the anterior mitral-valve leaflet (arrow). A four-chamber view with color Doppler (Panel B) shows mitral-valve regurgitation. A short-axis view (Panel C) shows the aortic valve (arrow) and an aortic-root pseudoaneurysm (asterisk). A short-axis view with color Doppler (Panel D) shows flow within the aortic-root pseudoaneurysm. A long-axis view (Panel E) shows the aortic valve (arrow) and an aortic-root pseudoaneurysm (asterisk). A long-axis view with color Doppler (Panel F) shows flow within the aortic-root pseudoaneurysm. LA denotes left atrium, LV left ventricle, RA right atrium, and RV right ventricle.



The New England Journal of Medicine is produced by NEJM Group, a division of the Massachusetts Medical Society.
Downloaded from nejm.org by TOM HSIUNG on March 15, 2026.
Copyright © 2026 Massachusetts Medical Society. All rights reserved, including those for text and data mining, AI training, and similar technologies.

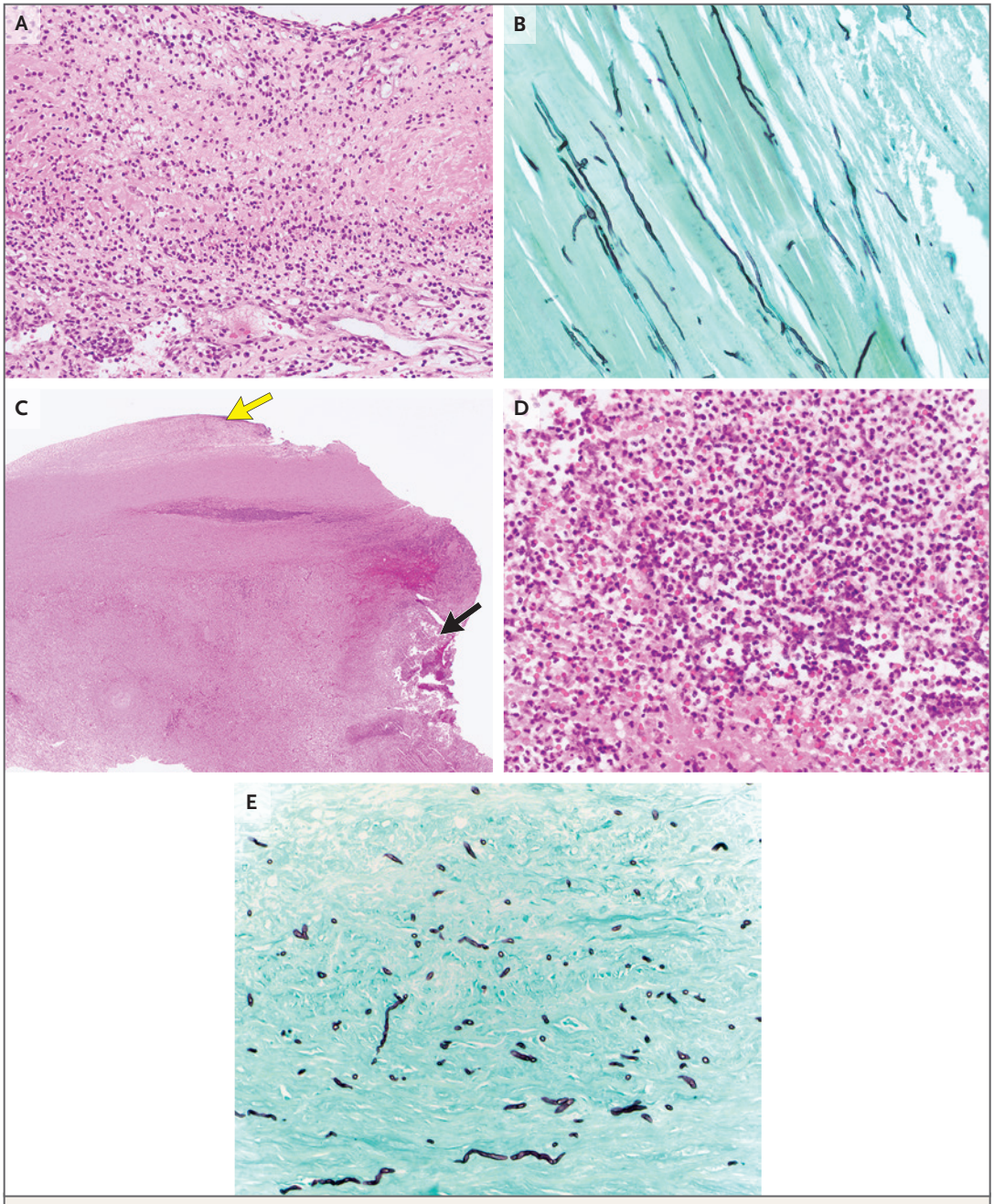


**Figure 4. Resection Specimens.**

Hematoxylin and eosin staining of the aortic valve (Panel A) shows acute and chronic inflammation. Grocott's methenamine–silver staining of the mitral valve (Panel B) shows fungal hyphae. Hematoxylin and eosin staining of the aorta (Panel C) shows expansion of the intima (yellow arrow) and an abscess cavity in the adventitia (black arrow). The abscess cavity in the adventitia is also visible at higher magnification (Panel D). Grocott's methenamine–silver staining of the aortic intima and media (Panel E) shows fungal hyphae.

revealed narrow, septate fungal hyphae with acute-angle branching. Histologic analysis of the aorta revealed thickening of the intima, marked neutrophilic infiltration of the media, and formation of an abscess cavity in the adventitia (Fig. 4C). The abscess cavity contained a neutrophil-predominant infiltrate with hemorrhage and necrosis (Fig. 4D), a finding indicative of an acute sup-



The New England Journal of Medicine is produced by NEJM Group, a division of the Massachusetts Medical Society.
Downloaded from nejm.org by TOM HSIUNG on March 15, 2026.
Copyright © 2026 Massachusetts Medical Society. All rights reserved, including those for text and data mining, AI training, and similar technologies.

purative aortitis.[17] Grocott's methenamine–silver staining of the aorta revealed fungal hyphae within the intima and media (Fig. 4E). The fungal hyphae present in both the cardiac valves and aorta had morphologic features consistent with aspergillus species.

## PATHOLOGICAL DIAGNOSIS

Fungal endocarditis involving the aortic and mitral valves with aortic-root abscess and contained rupture.

## FOLLOW-UP

*Dr. Melnitchouk:* Shortly after arrival in the ICU, diffuse coagulopathy with increased chest tube output and subsequent multipressor shock developed in the patient. Bedside echocardiography showed right ventricular failure in the context of fluid accumulation and compression of the heart chambers. The patient underwent emergency reexploration of the chest with packing of the pericardial cavity, and the chest was left open. Because her condition continued to worsen, treatment was switched to veno-arteriovenous ECMO support to mitigate the risk of upper-body hypoxemia (also known as the North–South syndrome or the harlequin syndrome). Subsequently, on postoperative days 3 and 4, she underwent two additional reexplorations of the chest and changes of packing owing to ongoing coagulopathy and bleeding. Progressive liver and kidney failure with persistent lactic acidosis developed despite the administration of broad-spectrum antimicrobial therapy. The goals of care were ultimately transitioned to comfort measures only, and she died 8 days after the initial presentation.

*Dr. Goldberg:* The patient, before her death, requested that her story be shared with others. She hoped that the lessons learned from her case could in some way help other providers and patients.

## FINAL DIAGNOSIS

Fungal endocarditis involving the aortic and mitral valves with aortic-root abscess and contained rupture.

This case was presented at the Medicine Case Conference.

Disclosure forms provided by the authors are available with the full text of this article at NEJM.org.

**AUTHOR INFORMATION**

[1] Heart and Vascular Institute, Mass General Brigham, Boston; [2] Department of Medicine, Harvard Medical School, Boston; [3] Department of Medicine, Massachusetts General Hospital, Boston; [4] Department of Radiology, Massachusetts General Hospital, Boston; [5] Department of Radiology, Harvard Medical School, Boston; [6] Department of Surgery, Massachusetts General Hospital, Boston; [7] Department of Surgery, Harvard Medical School, Boston; [8] Department of Pathology, Massachusetts General Hospital, Boston; [9] Department of Pathology, Harvard Medical School, Boston.

**REFERENCES**

1. Buoro S, Tombetti E, Ceriotti F, et al. What is the normal composition of pericardial fluid? Heart 2021;107:1584-90.
2. Case Records of the Massachusetts General Hospital (Case 32-2023). N Engl J Med 2023;389:1511-20.
3. Monroe EJ, Tailor TD, McNeeley MF, Lehnert BE. Needle embolism in intravenous drug abuse. Radiol Case Rep 2015;7:714.
4. Yen AF, Homer CM, Mohapatra A, Langnas E, Gomez A, Hendrickson CM. Embolic hypodermic needle causing traumatic cardiac tamponade: a case report. Crit Care Explor 2019;1(8):e0038.
5. Beck CS. Two cardiac compression triads. JAMA 1935;104:714-6 (https://jamanetwork.com/journals/jama/article-abstract/257566).
6. Kussmaul A. Uber schwielige Mediastino-Perikarditis und den paradoxen Puls. Berl Klin Wochenschu 1873;10:433-5.
7. Spodick DH. Acute cardiac tamponade. N Engl J Med 2003;349:684-90.
8. Roy CL, Minor MA, Brookhart MA, Choudhry NK. Does this patient with a pericardial effusion have cardiac tamponade? JAMA 2007;297:1810-8.
9. Kolski BC, Kakimoto W, Levin DL, Blanchard DG. Echocardiographic assessment of the accuracy of computed tomography in the diagnosis of hemodynamically significant pericardial effusions. J Am Soc Echocardiogr 2008;21:377-9.
10. Atar S, Chiu J, Forrester JS, Siegel RJ. Bloody pericardial effusion in patients with cardiac tamponade: is the cause cancerous, tuberculous, or iatrogenic in the 1990s? Chest 1999;116:1564-9.
11. Spodick DH. Bloody pericardial effusion: clinically significant without intrinsic diagnostic specificity. Chest 1999;116:1506-7.
12. Imazio M, Gaita F, LeWinter M. Evaluation and treatment of pericarditis: a systematic review. JAMA 2015;314:1498-506.
13. Mayosi BM, Burgess LJ, Doubell AF. Tuberculous pericarditis. Circulation 2005;112:3608-16.
14. Faria D, Freitas A. Tuberculous pericarditis. N Engl J Med 2018;378(20):e27.
15. Isselbacher EM, Preventza O, Hamilton Black J III, et al. 2022 ACC/AHA guideline for the diagnosis and management of aortic disease: a report of the American Heart Association/American College of Cardiology Joint Committee on Clinical Practice Guidelines. Circulation 2022;146(24):e334-e482.
16. Laing MK, Ti L, Marmel A, et al. An outbreak of novel psychoactive substance benzodiazepines in the unregulated drug supply: preliminary results from a community drug checking program using point-of-care and confirmatory methods. Int J Drug Policy 2021;93:103169.
17. Stone JR, Bruneval P, Angelini A, et al. Consensus statement on surgical pathology of the aorta from the Society for Cardiovascular Pathology and the Association for European Cardiovascular Pathology: I. Inflammatory diseases. Cardiovasc Pathol 2015;24:267-78.

*Copyright © 2026 Massachusetts Medical Society.*



The New England Journal of Medicine is produced by NEJM Group, a division of the Massachusetts Medical Society.
Downloaded from nejm.org by TOM HSIUNG on March 15, 2026.
Copyright © 2026 Massachusetts Medical Society. All rights reserved, including those for text and data mining, AI training, and similar technologies.